

# Treating Chronic Central Serous Chorioretinopathy

The goal is a treatment with increased success and decreased side effects.

BY MICHAEL KOSS, MD, FEBO

Central serous chorioretinopathy (CSC) is a sometimes-temporary visual impairment that is characterized by leakage of fluid in the center of the retina. This leakage leads to a blister, or serous detachment, in the macula that may lead to vision distortions and decreased visual acuity. Affecting 6 times more men than women, the majority of acute cases resolve spontaneously, with prognosis highly depending on presenting visual acuity.<sup>1</sup> Patients with visual acuities of 20/20 tend to remain at that level, while patients with initial visual acuities of less than 20/30 recover on average 2 to 3 Snellen lines over the following few years.

Although 60% to 75% of cases resolve spontaneously, visual acuity is at risk if the fluid has not reabsorbed after 3 months. However, a limited number of patients develop chronic CSC, and determining treatment for this group is challenging. I have applied a conservative approach with the systemic carbonic anhydrase inhibitor acetazolamide and topical dorzolamide (Trusopt, Merck), hoping that it might help the pathology. Due the nature of the disease, however, the efficacy of these drugs wears off over time in many of these patients, making this treatment path eventually equivalent to observation.

## CHRONIC CSC TREATMENT OPTIONS

More active treatment options include laser photocoagulation, photodynamic therapy (PDT), and anti-VEGF treatment. Conventional argon laser photocoagulation has been used for many years, with the aim of destroying and scarring any leaking vessels in the retinal pigment epithelium (RPE). The theory is that the healthy RPE can migrate and take over the pump function. In reality, photocoagulation often results in thermal damage to the photoreceptors and development of cho-

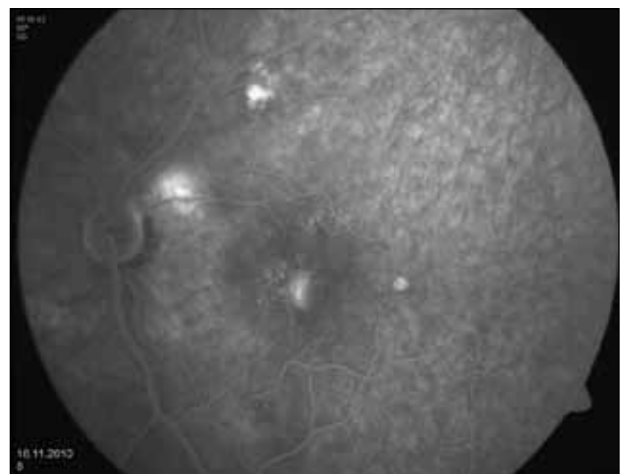


Figure 1. A 45-year-old man with a presumed duration of CSC of 12 months received 1 micropulse laser treatment to 3 locations using 1450 mW of power at 15% duty cycle for 200 ms.

roidal neovascularization, among other negative side effects.

Micropulse is a laser modality that chops a continuous stream of laser into a train of short bursts separated by pauses, preventing the buildup of thermal energy and damage to surrounding tissues. Rather than destroying cells, the laser is stimulating a biological response that promotes the restoration of RPE cells' integrity and physiology, resulting in the reabsorption of subretinal fluid.<sup>2,3</sup> Based on previous findings, my colleagues and I theorized that subthreshold diode micropulse (SDM) laser therapy could be an effective and safe treatment for chronic CSC. Guided by fluorescein angiography, I perform SDM with an 810-nm infrared diode laser (OcuLight SLx, Iridex Corp.) delivered through an Area

Centralis X0.94 lens (Volk Optical, Inc.). A threshold power is determined via a continuous-wave test burn in the nasal mid-periphery, and then the laser is switched from continuous-wave to micropulse emission mode, at 15% duty cycle, the threshold power (determined with the test burn) is doubled, and a 200-ms exposure duration is used (Figure 1).

PDT has been applied in the treatment of chronic CSC with satisfactory results.<sup>4,5</sup> Studies have shown that PDT induces choroidal vascular narrowing, reduces choroidal perfusion, and subsequently, reduces choroidal exudation.<sup>6,7</sup> Studies comparing half-fluence PDT and conventional PDT in chronic CSC found half-fluence therapy to be as effective as conventional PDT, while minimizing the deleterious effect on choriocapillaris perfusion and retinal thickness.<sup>8</sup>

The anti-VEGF drug bevacizumab (Avastin, Genentech) has been effective in decreasing subretinal fluid in the treatment of neovascular age-related macular degeneration and in some cases of CSC.<sup>9</sup> The pharmacologic action is not fully understood, but the benefit-to-risk ratio could potentially offer a preferable treatment modality.

### **SDM THERAPY VS HALF-FLUENCE PDT**

My colleagues and I recently completed a study of 31 eyes randomized to SDM therapy, half-fluence PDT therapy, or observation over a period of 16 weeks. Preliminary results show that both SDM and half-fluence PDT led to significant increases in visual acuity and decreases in fluorescein angiography leakage compared with the control group. Publication of the results is expected later this year.

### **SDM THERAPY VS ANTI-VEGF THERAPY**

Last year, my colleagues and I published a comparison of SDM vs intravitreal injections of bevacizumab in the treatment of CSC in 52 eyes of 52 patients.<sup>10</sup> All patients had symptoms for a minimum of 5 months. Sixteen eyes of 16 patients received treatment with SDM at the active leakage site, 10 eyes received an intravitreal injection of 1.25-mg of bevacizumab, and 26 eyes of 26 patients in the study underwent observation, waiting to see if the pathology resolved spontaneously.

We found that SDM photocoagulation was superior to injections of bevacizumab in the treatment of CSC. After 10 months, 12.5% of the group that received SDM therapy had persistent leakage, compared with 60% of the

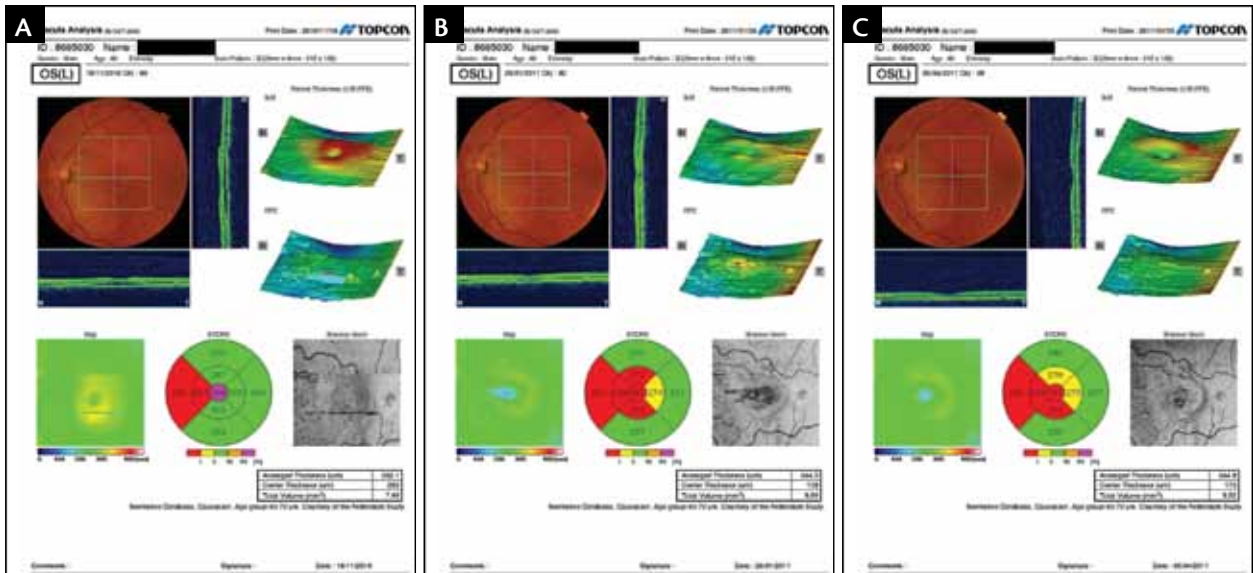


Figure 2. OCT scans at baseline (A), 8 weeks (B), and 16 weeks (C) show a decrease in retinal thickness of 17.3 μm, a decrease in fluid volume of 0.5 mm<sup>3</sup>, and an increase of 12 ETDRS letters read.

bevacizumab group and 92% of the control group. Central macular thickness decreased by a mean 94 μm in the SDM group, 38 μm in the bevacizumab group, and did not change in the control group. Mean best corrected visual acuity improved more than 6 ETDRS letters in the SDM group, decreased by 1 letter in the bevacizumab group, and decreased by 2 letters in the control group.

A presentation of these data is available by scanning the QR code on the right, or via the link.



**CONCLUSION**

Chronic CSC requires a tailored and delicate treatment approach that addresses the sites of leakage and the state of the RPE. One of the most important goals of CSC treatment in the past has been to find something that is effective without also doing harm. With SDM treatment, we have at least

1 means that meets these criteria. In our study, we did not see any damage to the tissue following treatment, despite applying a high power beam right over the fovea.

Today, when patients come into the clinic, I tell them about the results of our study and that the worst outcome was no effect. Patients who morphologically appeared to have very old CSC appear to be the least promising as candidates for SDM therapy. In the 3 different groups in our study, we did not see any scotomas resulting from SDM. ■

Michael Koss, MD, FEBO, is currently a visiting researcher at the Doheny Eye Institute in Los Angeles, where he is primarily investigating the potential of human embryonic stem cell transplantation for the treatment of dry AMD. He may be reached at michael.koss@me.com.



Weigh in on this topic now!



Direct link: <https://www.research.net/s/RetinaToday12>

Which treatment produces the most promising results for chronic central serous chorioretinopathy?

- Photodynamic therapy
- Subthreshold diode micropulse laser
- Anti-VEGF injection
- None of the above

- Liew G, Quin G, Gillies M, Fraser-Bell S. Central serous chorioretinopathy: a review of epidemiology and pathophysiology. *Clin Experiment Ophthalmol.* 2013;41(2):201-214. doi: 10.1111/j.1442-9071.2012.02848.x. Exp 2012 Sep 21.
- Dorin G. Subthreshold and micropulse diode laser photocoagulation. *Semin Ophthalmol.* 2003;18(3):147-153.
- Flaxel C, Bradle J, Acott T, Samples JR. Retinal pigment epithelium produces matrix metalloproteinases after laser treatment. *Retina.* 2007; 27(5):629-634.
- Yannuzzi LA, Slakter JS, Gross NE, et al. Indocyanine green angiography-guided photodynamic therapy for treatment of chronic central serous chorioretinopathy: a pilot study. *Retina.* 2003; 23(3):288-298.
- Taban M, Boyer DS, Thomas EL. Chronic central serous chorioretinopathy: photodynamic therapy. *Am J Ophthalmol.* 2004;137(6):1073-1080.
- Chan WM, Lam DS, Lai TY, Tam BS, Liu DT, Chan CK. Choroidal vascular remodelling in central serous chorioretinopathy after indocyanine green guided photodynamic therapy with verteporfin: a novel treatment at the primary disease level. *Br J Ophthalmol.* 2003;87(12):1453-1458.
- Schmidt-Erfurth U, Michels S, Barbazetto I, Laqua H. Photodynamic effects on choroidal neovascularization and physiological choroid. *Invest Ophthalmol Vis Sci.* 2002;43:830-841.
- Shin JY, Woo SJ, Yu HG, Park KH. Comparison of efficacy and safety between half-fluence and full-fluence photodynamic therapy for chronic central serous chorioretinopathy. *Retina.* 2011;31(1):119-126.
- Artunay O, Yuzbasioglu E, Rasier R, Sengul A, Bahcecioglu H. Intravitreal bevacizumab in treatment of idiopathic persistent central serous chorioretinopathy: a prospective, controlled clinical study. *Curr Eye Res.* 2010;35(2):91-98.
- Koss MJ, Berger I, Koch FH. Subthreshold diode laser micropulse photocoagulation versus intravitreal injections of bevacizumab in the treatment of central serous chorioretinopathy. *Eye.* 2012;26(2):307-314.