

Long-term Efficacy of Micropulse Diode Transscleral Cyclophotocoagulation in the Treatment of Refractory Glaucoma

Maria Cecilia Aquino¹ & Paul Chew^{1,2}

Department of Ophthalmology, National University Health System, ¹National University Hospital & ²National University of Singapore,

Purpose

The objective of this study is to evaluate and present the long-term efficacy of micropulse diode transscleral cyclophotocoagulation (MPCPC) in subjects with refractory glaucoma treated from a prior prospective study.

Study Design

Retrospective Case Series

Study Population

All patients with refractory, end-stage glaucoma, unresponsive to alternative treatment.

Methods

This is a retrospective review of the cases treated with micropulse cyclophotocoagulation in a previous randomized exploratory study¹. Patients with advanced glaucoma having IOP of >21 mmHg on maximal, tolerated, medical therapy with or without previous surgical intervention and visual acuity of 6/60 or worse were included. Micropulse diode transscleral cyclophotocoagulation (MPCPC) was delivered with laser power set at 2Watts, 100s pulse envelop with 0.5ms ON and 1.1ms OFF delivering 62.6Joules per treatment (Iris Medical Instruments Inc., Mountain View, CA, USA) Intraocular pressure (IOP) and number of anti-glaucoma eye drops were recorded from 6 months to the last follow-up visit of about 6.5 years (range 36 – 96 months).

Results

There were 14 patients (61%) out of the 23 treated with MPCPC in the prior randomized study who had follow-up review up to 78 months. Mean IOP recorded was listed in Table 2 and IOP trend was shown in Figure 2. The number of eye drops was presented in Figure 3. Attrition rate after 6.5 years was 9 (39%) out of 23 patients with 5 lost to follow-up, 2 deceased & 2 had ocular surgery (1glaucoma drainage implant surgery & 1 enucleation).

Significant IOP reduction was observed at all time points compared to pre-treatment IOP. About 67% of the 14 patients had 39% (range 31-68%) mean IOP reduction from baseline even after a mean of 78 months. The remaining 33% treated patients had 17% (range 9-24%) IOP reduction on the average. No significant difference in eye drops noted pre & post laser.

Results

Table 1. Patient demographics & characteristics

Age	
Mean (SD)	59.9(15.7)
Min: Max	23:80
Sex, n (%)	
Male	7 (50%)
Female	7 (50%)
Ethnicity, n (%)	
Chinese	11 (78%)
Malay	3 (22%)
Eyes, n (%)	
Right	4 (29%)
Left	10 (71%)
Diagnosis, n (%)	
POAG	2 (14%)
PACG	5 (36%)
NVG	4 (29%)
Juvenile glaucoma	2 (14%)
Secondary glaucoma	1 (7%)

Table 2. IOP pre & post MPCPC

Patient	PRE LASER	POST LASER 6 MOS.	POST LASER 12 MOS.	POST LASER 18 MOS.	POST LASER 78 MOS.
1	42	22	17	18	23
2	50	26	24	22	38
3	66	20	20	28	28
4	53	30	18	23	21
5	62	18	18	24	28
6	56	20	18	20	23
7	34	24	14	16	16
8	22	18	18	16	20
9	30	12	14	14	26
10	26	14	16	16	18
11	32	12	12	14	21
12	73	46	32	28	56
13	22	7	12	16	18
14	38	24	22	20	12
Mean	43.3	20.9	18.2	19.6	24.8
Sd	16.8	9.5	5.3	4.8	11.0
p*		0.00	0.01	0.00	0.00

*Student's Ttest

Discussion

Micropulse diode transscleral cyclophotocoagulation has emerged as a new treatment option for glaucoma.^{1,3} Instead of the conventional, continuous train of high intensity energy application, a series of repetitive short pulses of energy with rest period in between is delivered in a micropulse mode. Early works of Tan, Chew et al.³ found it effective & safe in lowering IOP by ≥30% with consequent reduction in medications. In a prior randomized comparison study¹, MPCPC treated eyes resulted to 45% IOP reduction from baseline but with similar number of medications after 18 months.

This retrospective review of the same group of patients from the randomized comparison of Aquino et al. with longer follow-up of 78 months showed 39 % IOP reduction. Frezzotti et al.² reported a 38.7% IOP reduction after 42 months of continuous wave diode transscleral CPC without a change in the number of glaucoma medications.

Results

Figure 1. Micropulse Diode Cyclophotocoagulation

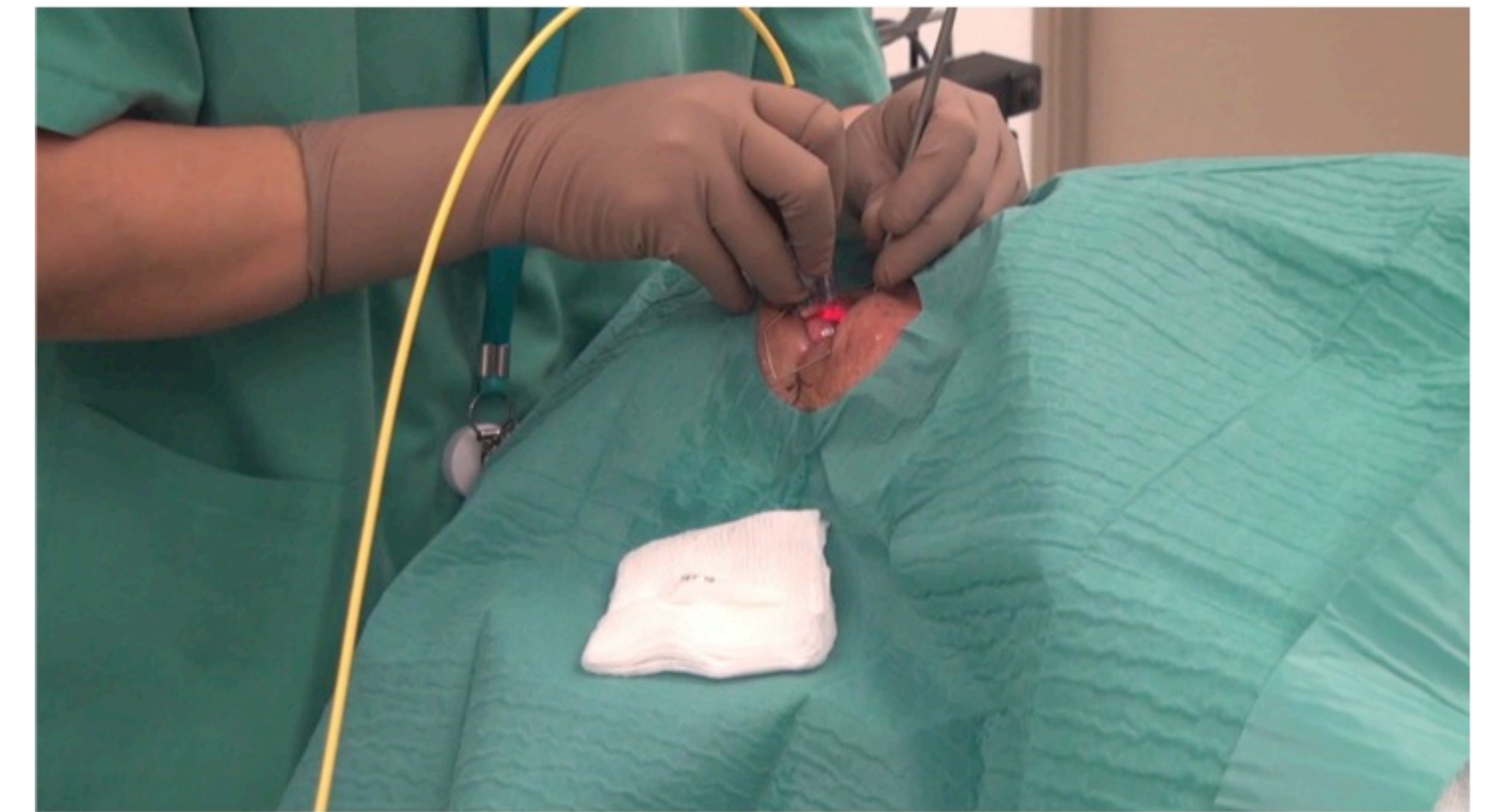


Figure 2. Mean IOP over time after MPCPC

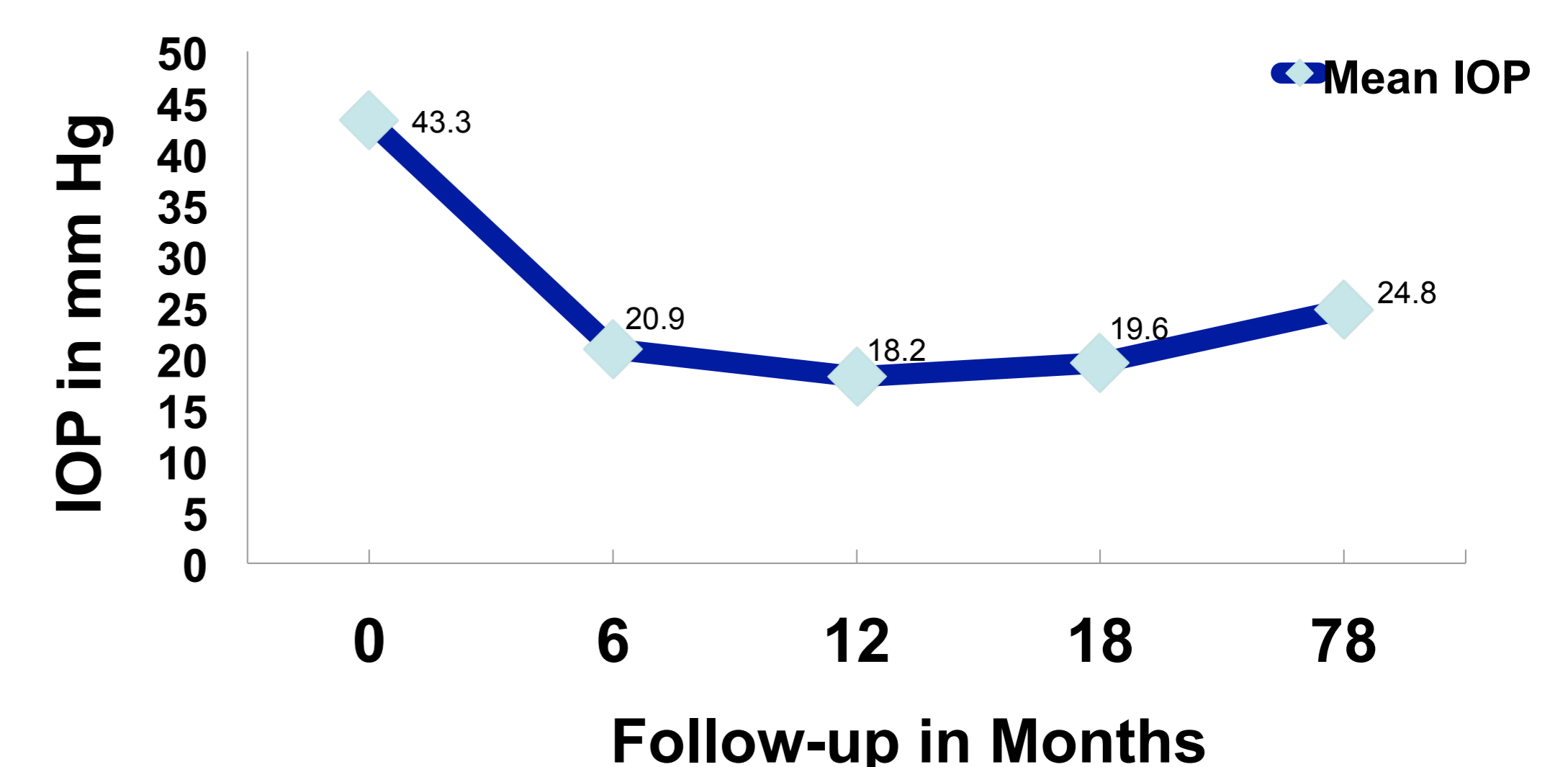
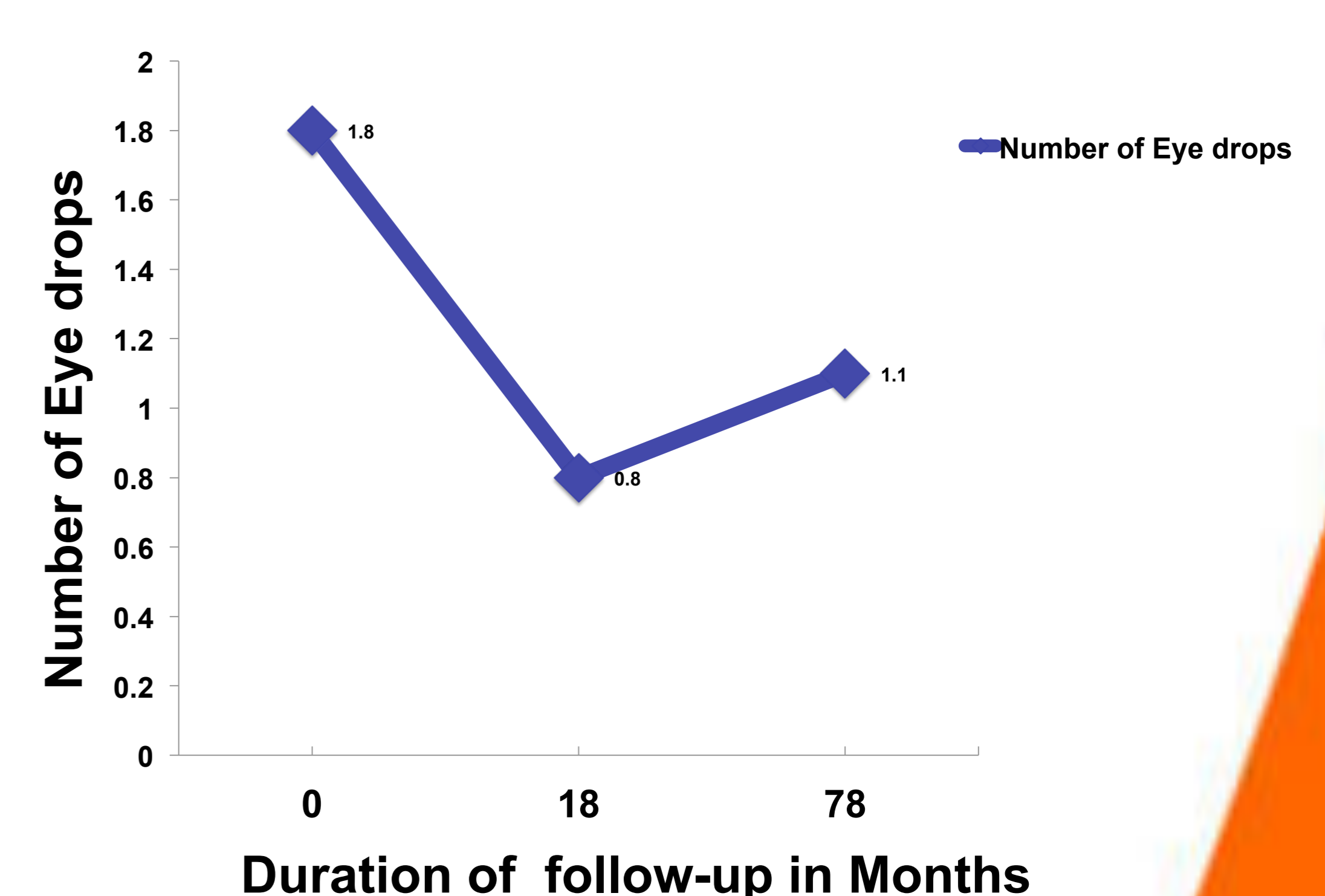


Figure 3. Number of Medications



Conclusion

Micropulse diode transscleral cyclophotocoagulation was effective in the long term IOP control of refractory glaucoma.

This retrospective review was limited by the small number of sample size and the attrition rate after many years of follow-up.

References

1. MCD Aquino, K Barton, AM Tan, C Sng, X Li, SC Loon, & PTK Chew. Micropulse versus continuous wave transscleral diode cyclophotocoagulation in refractory glaucoma: a randomized exploratory study. *Clin Exptl Ophthalmol* 2015; 43: 40-46.
2. P Frezzotti, V Mittica, G Martone et al. Longterm follow-up of diode laser transscleral cyclophotocoagulation in the treatment of refractory glaucoma. *Acta Ophthalmologica* 2010; 88:150-155.
3. AM Tan, M Chockalingam, MCD Aquino, Z Lim, JLS See & PTK Chew. Micropulse transscleral cyclophotocoagulation in the treatment of refractory glaucoma. *Clin Exptl Ophthalmol* 2010; 38:266-272.
4. Moorman CM and Hamilton AM. Clinical applications of the Micropulse diode laser. *Eye* 1999 Apr; 13(pt2): 145-50.